



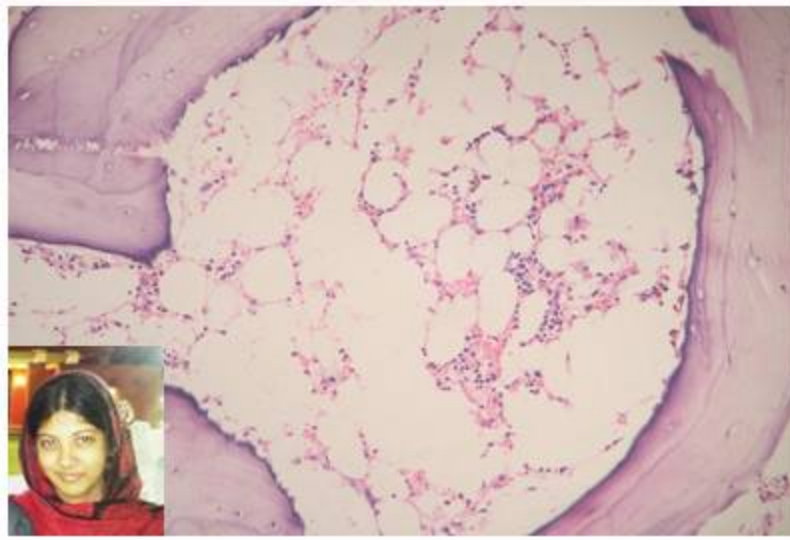
# CME on Bone Marrow Trephine Biopsy interpretation

## Department Of Pathology, JIPMER

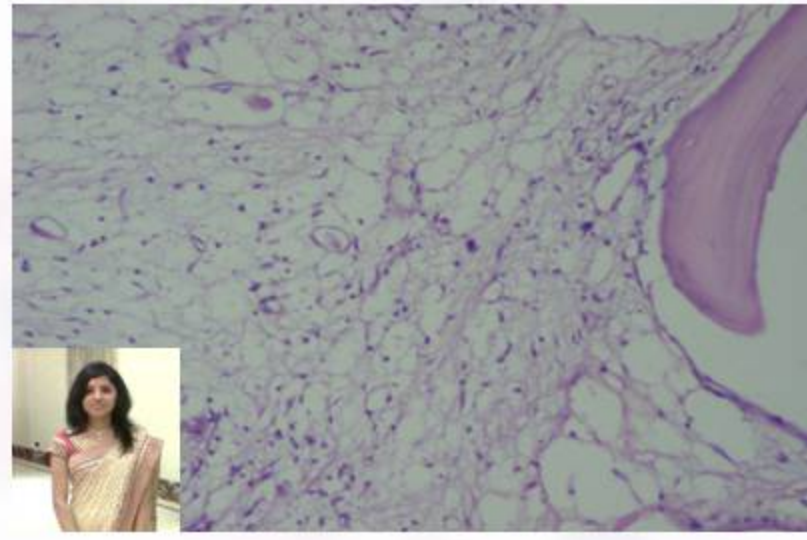
29-11-2014 - 2pm, Pasteur Theatre



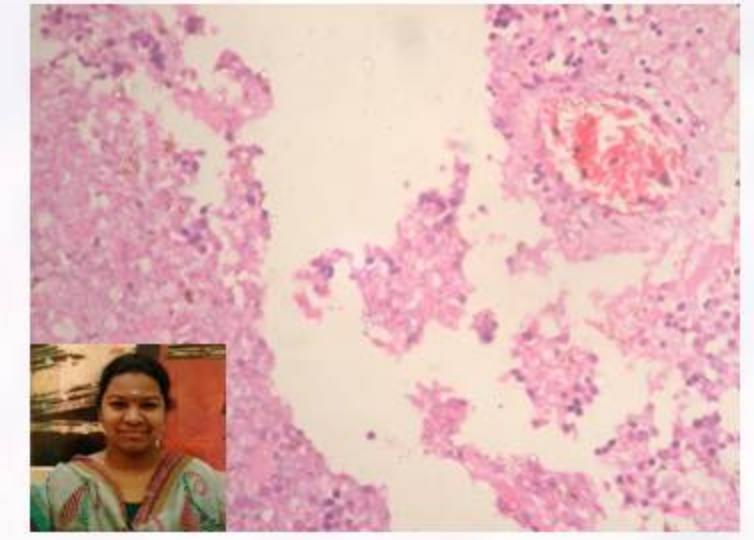
- PROCESSING AND INDICATION - Dr. Sajini Elizabeth Jacob
- NORMAL HISTOLOGY - Dr. Rakhee Kar
- CASE DISCUSSIONS - Dr. Debdatta Basu



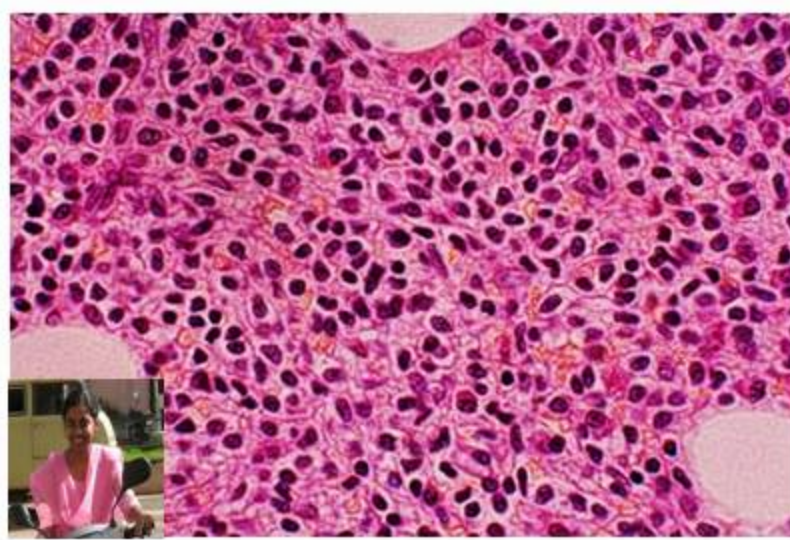
Hypoplastic marrow



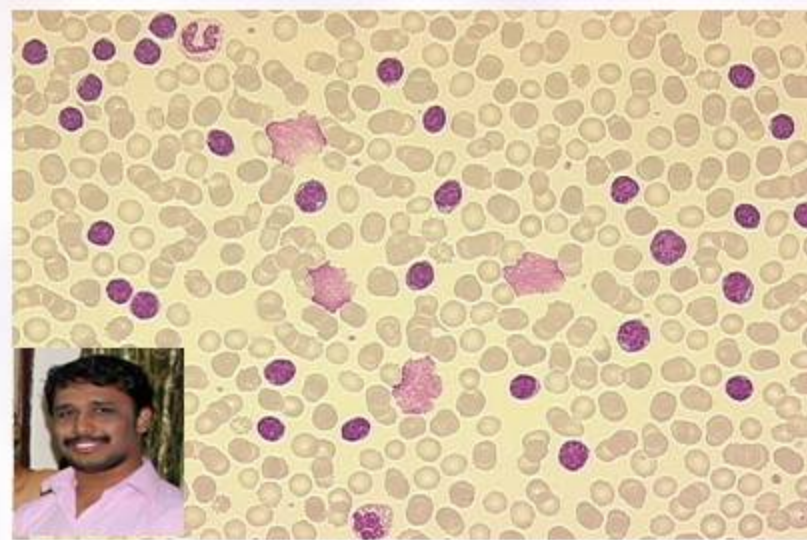
Pancytopenia with Blasts



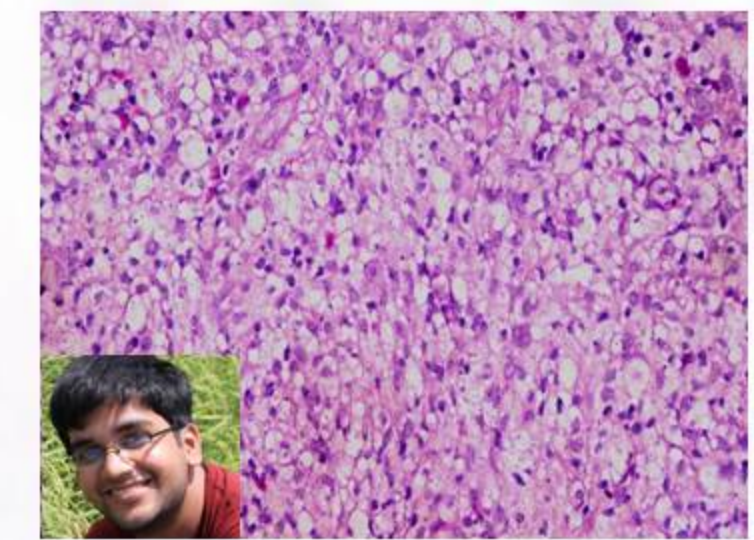
Febrile Pancytopenia



Pancytopenia with Splenomegaly



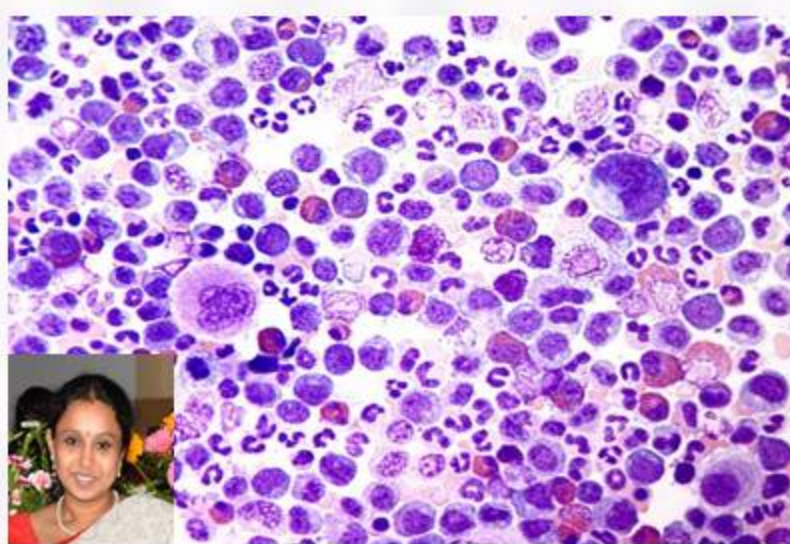
Marrow in NHL



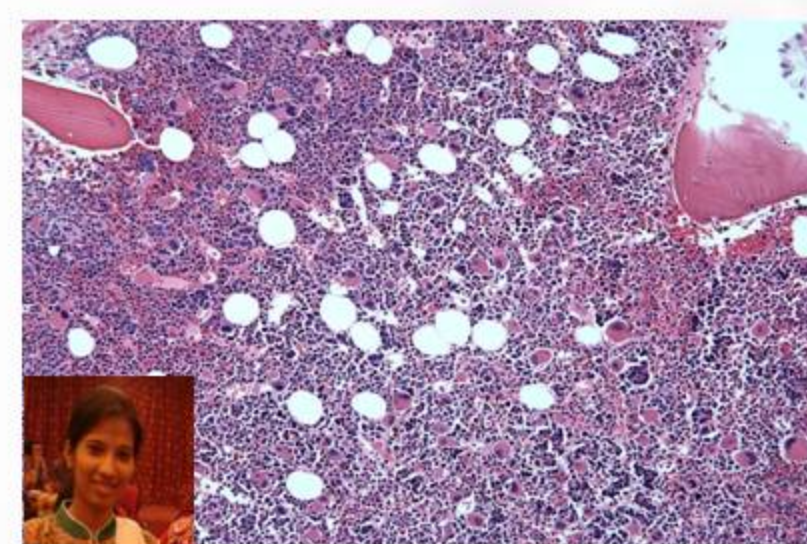
Marrow in Hodgkins



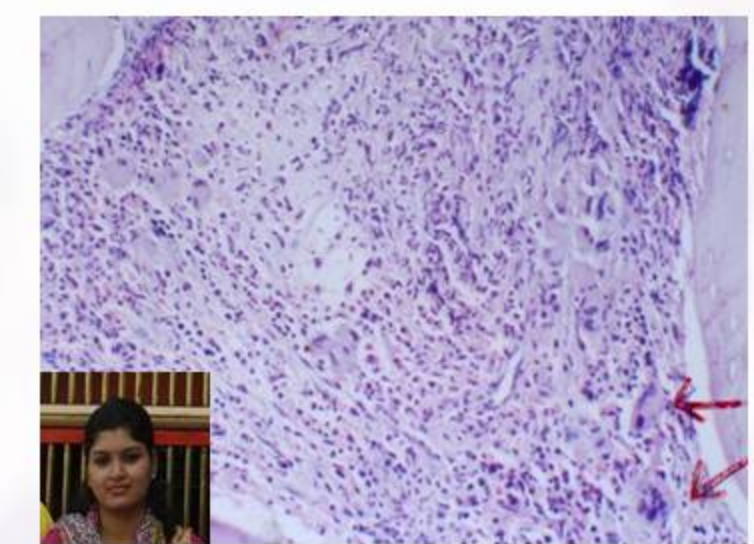
### Refresh & Relax



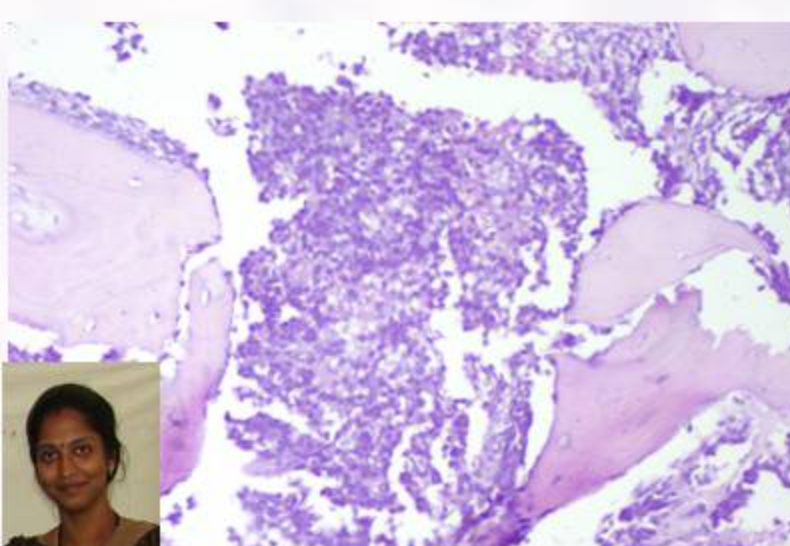
Chronic Myeloid Leukemia



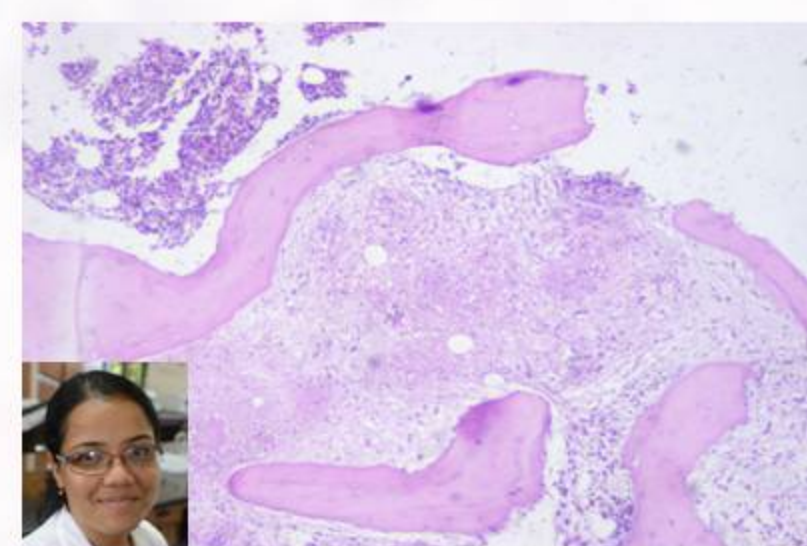
Other myeloproliferative neoplasms




Myelofibrosis



Metastasis



PUO



QUIZ